CoxHealth Vascular Conference

2018

Evaluation and Management of

Thoracic Aortic
Injury and Disease

Thoracic Aorta

- Enormous changes in management in the last decade!
- No longer is every injury or abnormality an absolute surgical emergency
- Open repair with thoracotomy is rarely indicated
- Endovascular techniques are almost always preferred
- Medical management followed by carefully timed surgical repair is now the standard of care in the absence of active bleeding/life threatening progression

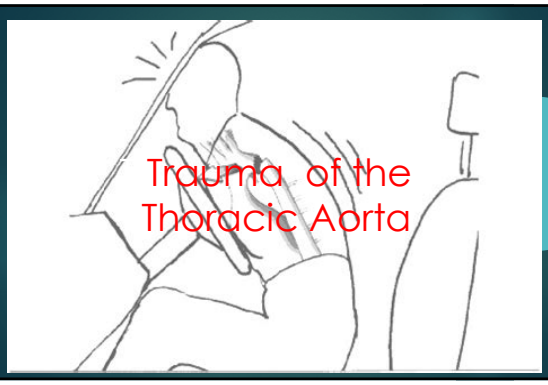

Trauma of the Thoracic Aorta

- J Vasc Surg. 2011 Jan;53(1):187-92. doi: 10.1016/j.jvs.2010.08.027. Epub 2010 Oct 25.
- **Endovascular repair of traumatic thoracic aortic injury: clinical practice guidelines of the Society for Vascular Surgery.**
- Lee WA[1], Matsumura JS, Mitchell RS, Farber MA, Greenberg RK, Azizzadeh A, Murad MH, Fairman RM.
- The Society for Vascular Surgery® pursued development of clinical practice guidelines for the **management of traumatic thoracic aortic injuries with thoracic endovascular aortic repair.** The systematic review included 7768 patients from 139 studies. The **mortality rate was significantly lower in patients who underwent endovascular repair**, followed by open repair, and nonoperative management (9%, 19%, and 46%, respectively, P < .01). Based on the overall very low quality of evidence, the committee suggests that **endovascular repair of thoracic aortic transection is associated with better survival and (dependent) lack of spinal cord ischemia, graft failure, graft, and systemic infections** compared with open repair or nonoperative management (Grade 2, Level C). On these select matters, the majority opinions of the committee suggest urgent **chest tube/drainage, ventilation of other injuries, observation of external aortic defects**, selective (vs routine) revascularization in cases of left subclavian artery coverage, and that spinal drainage is not routinely required in these cases.

Journal of Vascular Surgery
Volume 55, Issue 1, January 2012, Pages 47-54

Clinical research study
From the Society for Vascular Surgery

A new classification scheme for treating blunt aortic injury

Presented at the 2010 Vascular Annual Meeting of the Society for Vascular Surgery, Boston, Mass, June 10, 2010.

Benjamin W.Starnes, MD, FACS;
S. Rachel .Lundgren, MD; Martin Gunn, MBChB; et al

Minimal Aortic Injury?

Absent External Contour Abnormality			Present External Contour Abnormality		
Type of Aortic Injury	*Definition*	*Example*	*Type of Aortic Injury*	*Definition*	*Example*
Intimal Tear	No aortic external contour abnormality: tear and/or associated thrombus is < 10mm	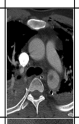	**Pseudoaneurysm**	Aortic external contour abnormality: contained	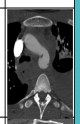
Large Intimal Flap	No aortic external contour abnormality: tear and/or associated thrombus is > 10mm		**Rupture**	Aortic external contour abnormality: not contained, free rupture	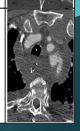

AORTIC TRANSECTION MANAGEMENT

"TREAT THE TRANSECTION LIKE A DISSECTION"

This Concept Becomes Very Important….

- The management of Blunt Aortic Injury

&

- Acute Aortic Syndrome….
- …..are very much alike!

Medical Management

- Aggressive blood pressure **and** heart rate control
- Address the pain!
- Volume resuscitation for adequate pre-load & rate control
- Rapidly evaluate for—and urgently address—associated injuries

Blood Pressure Management

- Single most critical aspect of clinical care before surgery!
- Goals: SBP 100-120, HR <60
- B blockers ARE the initial drug of choice (esmolol)
- Ca++ channel blockers if B blockers contraindicated (COPD, asthma)
- Add afterload reduction (nitroprusside, cleviprex) if needed AND AFTER B blockade

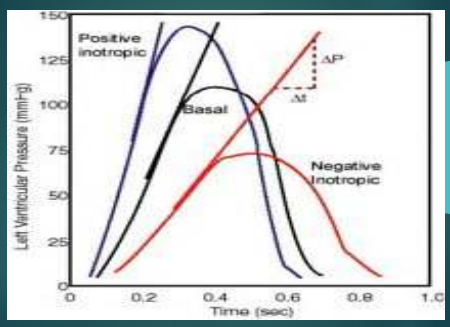

BP? Can be complicated in trauma….

- Hypotension a more common problem in polytrauma
- B blockade can be tricky…..
- …and most commonly needs to be done gingerly…
- …while aggressively managing associated injuries

Acute Aortic Transection
Clinical Case

- Middle aged male who rear ended a PARKED semi, at highway speeds
- In ED, ultrasound revealed extensive intrabdominal fluid; taken emergently to the OR
- At laparotomy, liver laceration packed, right tib-fib fracture then stabilized with ex-fix, left open radius fx addressed
- CT head and chest done after OR, thoracic aortic transection discovered
- Resuscitated/Nutrified overnight
- Back to OR the next day for aortic repair

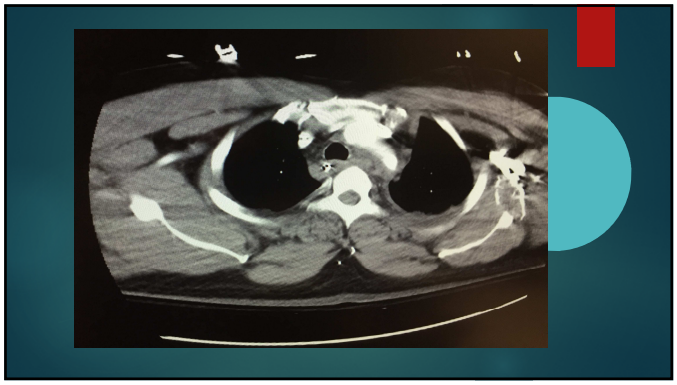

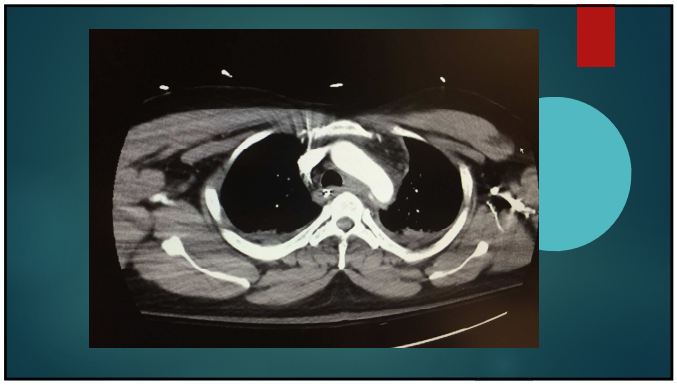

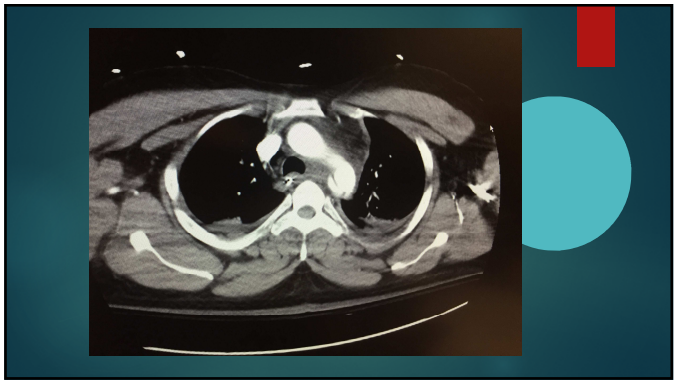

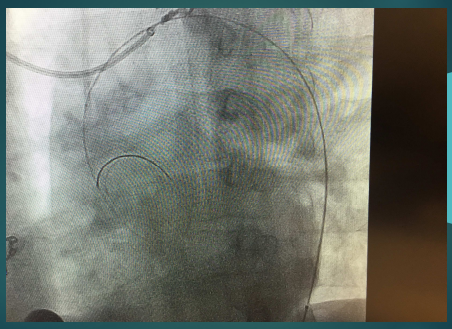


LT

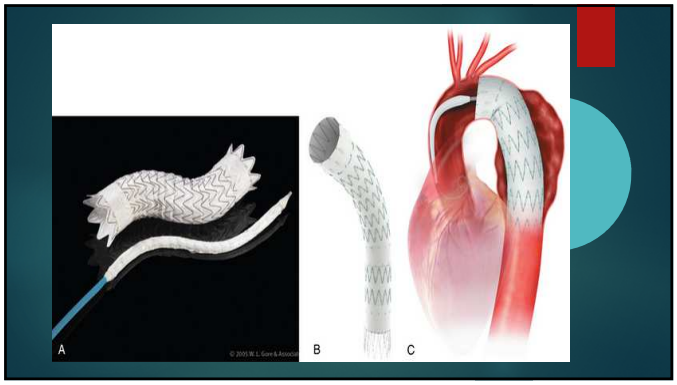
A
B
C

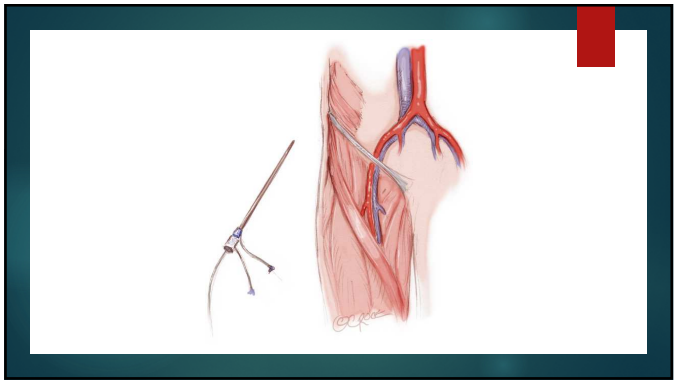

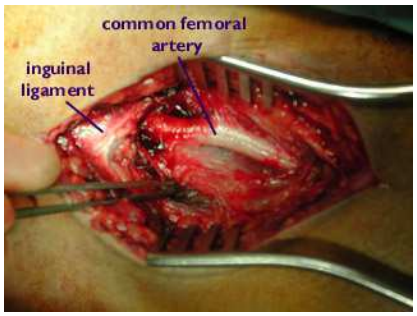
common femoral
artery
inguinal
ligament

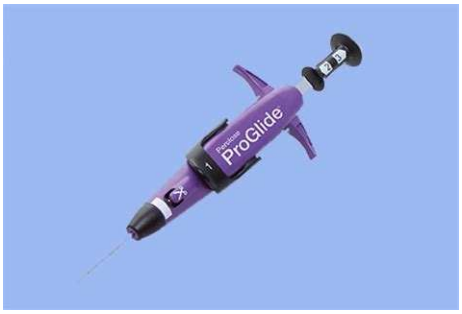
ProGlide



- J Vasc Surg Cases Innov Tech. 2017 Jan 10;3(1):11. doi: 10.1016/j.jvscit.2016.04.008. eCollection 2017 Mar.
- **Endovascular repair of a thoracic aortic transection 31 years after blunt trauma.**
- Bell J[1], Schmittling ZC[1], Mullins JR[1], Vorhies RM[1].

Delayed Aortic Injury Presentation

- At age 16 was involved in a head on mva; in coma for 6 weeks
- Normal life until age 47, when she developed hemoptysis & presented to her PCP
- CXR was markedly abnormal, so a CTA was obtained emergently
-
- Hemoptysis was due to rupture of thoracic pseudoaneurysm into pulmonary vein!
- Repaired emergently due to active hemoptysis
- Discharged on post op day 2
- Rapid resolution of aneurysm with shrinkage on CT at follow up

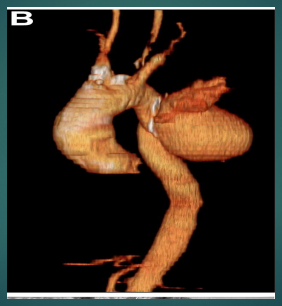

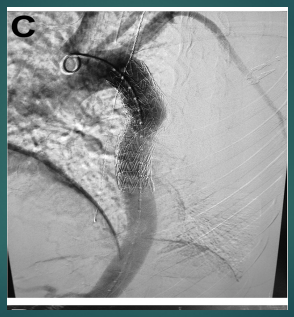

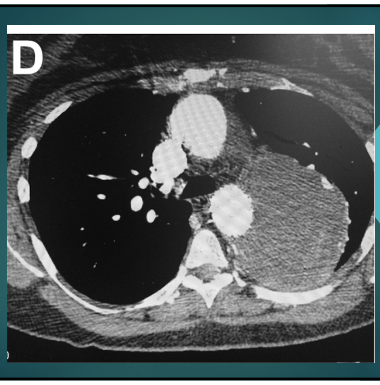

Acute Aortic Syndrome

- Intramural Hematoma
- Penetrating Ulcer
- Dissection

Acute Aortic Syndrome

- Most common aortic emergency
- Incidence ~4.0 per 100,000 patient-years in the general population
- Incidence with age: 27 per 100,000 patient-years in ages 64-74 years, 35 per 100,000 patient-years at ≥75 years
- Dissection comprises 85% of all AAS

Intramural Hematoma

- IMH begins with rupture of the *vasa vasorum*, causing bleeding into the aortic media
- Usually associated with severe ASO, smoking, hypertension
- IMH can progress to acute aortic dissection if the intimal layer ruptures, causing an entry tear.
- The presence of an entry tear is pathognomonic for acute aortic dissection (and is an indication for endograft repair)
- However, most acute aortic dissections do NOT occur as a result of IMH

IMH: diagnosis and Management

- CTA and MRI are the gold standards for the diagnosis of IMH
- CT identification of intimal defects (discrete erosions of the vessel wall) is associated with progression to acute dissection.
- Early mortality of patients with IMH is ~8% for medical management, ~17% for open surgical repair and ~2% for TEVAR
- Endograft placement is reserved for progression or uncontrolled pain

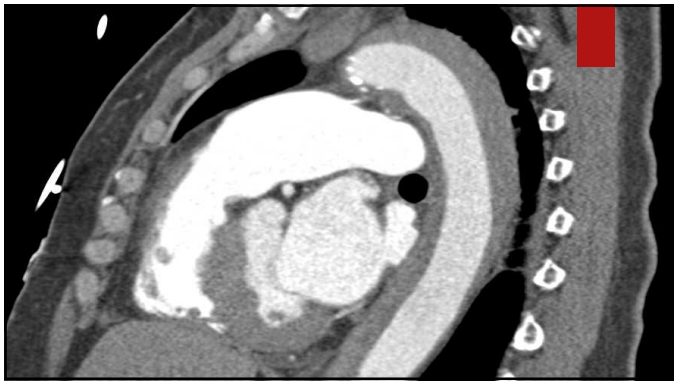

Penetrating Ulcer

- Comprises about 5% of all AAS cases
- Associated with ASO, hypertension, smoking
- Presents with pain OR noted on imaging while asymptomatic
- Management is identical to that of IMH and Dissection

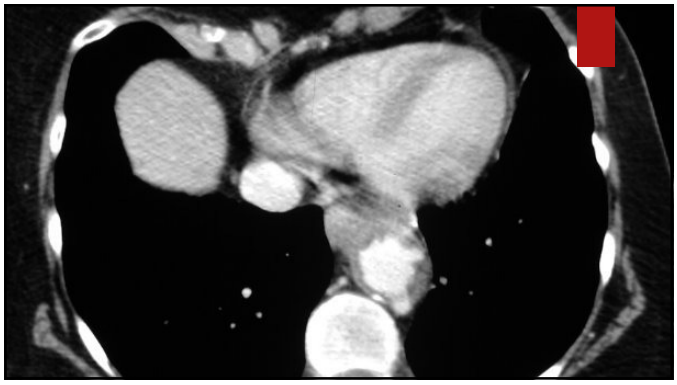

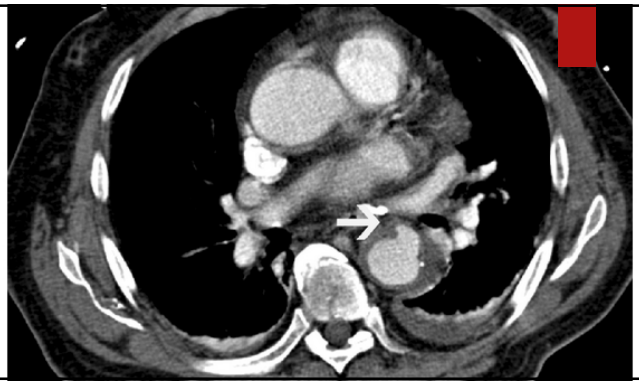

Dissection

- Most common etiology of AAS
- Median age at presentation: 61 years; more common in men
- Hypertension is the most common comorbidity, then smoking, chronic renal insufficiency, COPD, and stroke or transient ischemic attack
- Almost all patients with an acute dissection will have hypertension, often severe, at presentation
- Young patients with a dissection frequently have been abusing cocaine or methamphetamines

Dissection: History

- Descriptions of aneurysm and dissection date back as early as the 2nd century during the time of Galen
- More "recent" reports were described by Vesalius in 1557, followed by Nichols in 1732, who detailed the process of aortic dissection.
- 1761: Morgagni reported detailed pathologic features of a patient with a ruptured aorta.
- True understanding of aortic pathology began with the dissertation by Shennan[2] in 1934, which included a description of penetrating atheromatous plaques of the thoracic aorta.
- First successful management of aortic dissection by DeBakey in 1955

Dissection: Presentation

- Patients with AAD, IMH, penetrating aortic ulcer, TAA present with similar signs/symptoms.
- Sudden onset of severe, sharp chest pain is the classic presenting symptom (~75% of patients)
- Anterior chest pain: IMH, type A dissection
- Type B dissections: back and abdominal pain
- Abrupt onset, the most sensitive pain descriptor, is present in approximately 90% of patients.
- Other common presentations: syncope (13% of type A AADs) abdominal pain (22% of type A AADs and 43% of type B AADs)
- Contrary to popular thinking pain of acute dissection most commonly described as "sharp" vs "tearing" or "ripping"

Dissection in Pregnancy

- Rarely, pregnancy can be associated with AAD.
- Aortic dissections occurring in pregnant females typically occur in the third trimester but can also develop in the early postpartum period.
- Result of pregnancy-related hemodynamic changes (increased cardiac output, heart rate) in the setting of an already weakened aortic wall from underlying connective tissue disease
- After 30 weeks of gestation, pregnant females with dissection involving the ascending aorta should undergo emergent Cesarean section before surgical repair of the aorta.[2]

Dissection: Underlying Pathology

- Genetic conditions associated with AAS:
- Marfan syndrome (Fibrillin degradation)
- Ehlers-Danlos syndrome (Type III procollagen)
- Familial aortic dissection
- Annuloaortic Ectasia
- Loeys-Dietz Syndrome

Dissection: Diagnosis

- Suspect the diagnosis!
- About 30% of dissections (if not more) are missed on initial presentation
- "The great mimic": ddx of aortic dissection is that of chest pain
- 90% of dissection patients will have an abnormal CXR
- CTA is (really, practically) the gold standard
- MR and TEE are very helpful in those patients for whom CTA is problematic

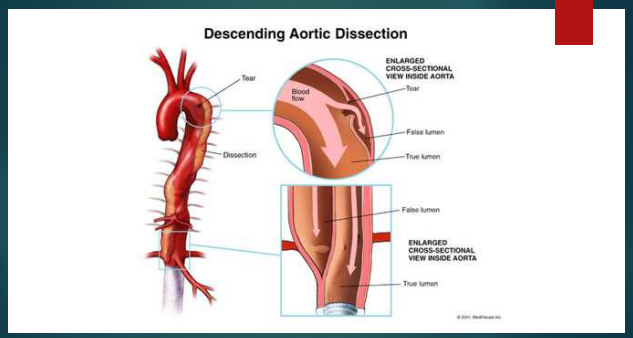

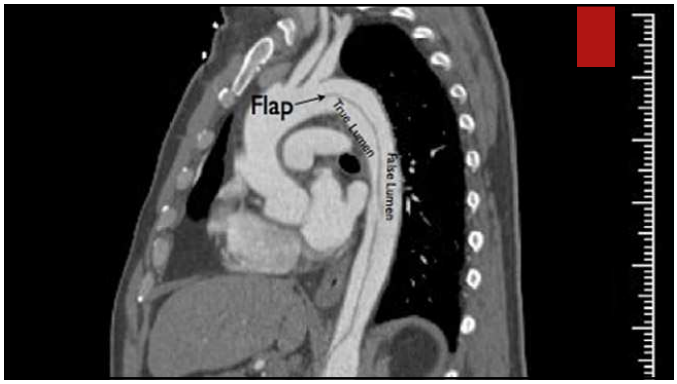

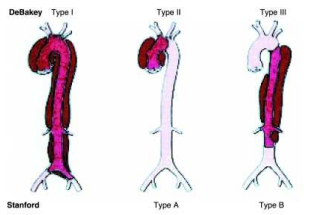

Stanford

DeBakey

Type I Originates in the ascending aorta, propagates at least to the aortic arch and often beyond it distally

Type II Originates in and is confined to the ascending aorta

Type III Originates in the descending aorta and extends distally down the aorta or rarely retrograde into the aortic arch and ascending aorta

Stanford

Type A All dissections involving the ascending aorta, regardless of the site of origin

Type B All dissections not involving the ascending aorta

Dissection: Classification

Dissection: Management (Type B)

- ICU admission
- Aggressive BP management
- Pain control
- Hydration/resuscitation as appropriate
- Evaluation of visceral and distal perfusion

Dissection: Intervention

- Uncontrolled pain
- Uncontrolled hypertension/steadily increasing BP med requirements
- Evidence of visceral ischemia
- Evidence of distal ischemia
- Progression of dissection on follow up imaging (1 week 1 month, 6 months, annually)

Dissection: Endograft

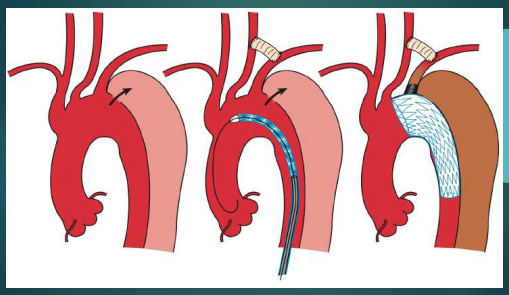

Aberrant

Right Subclavian

Artery

What Is ARSA?

--MOST COMMON ANOMALY OF THE AORTIC ARCH

--2/3 ARE ASYMPTOMATIC

PRESENTATION

- "INCIDENTALOMA"
- DYSPHAGIA LUSORIA
- COUGH
- UPPER EXTREMITY ISCHEMIA

ANATOMY

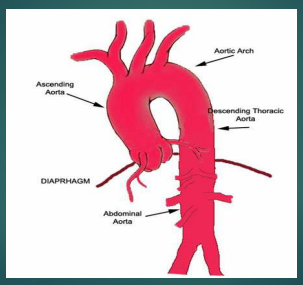

ANATOMY II

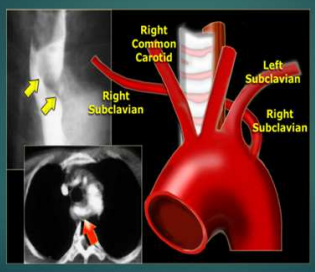

ANATOMY: ANGIO

INDICATIONS FOR INTERVENTION

-- SYMPTOMATIC PATIENTS

-- DILATATION OF THE DUCT OF KUMMERALL

TRADITIONAL MANAGEMENT

- RIGHT CAROTID-SUBCLAVIAN BYPASS
- THORACOTOMY
- GRAFT INTERPOSITION REPAIR OF THE DESCENDING AORTA

CAROTID-SUBCLAVIAN BYPASS

THORACOTOMY

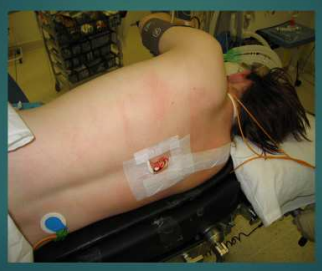

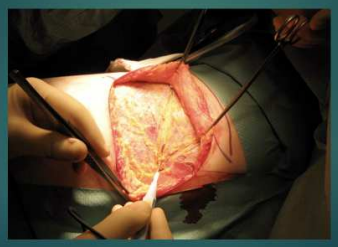

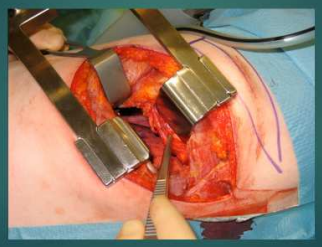

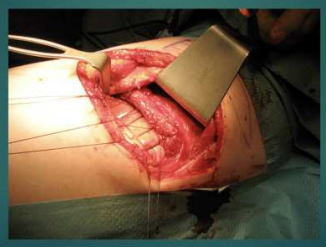

POST SURGICAL APPEARANCE

Maybe we can…

…Should?

……..Do things differently?

HYBRID PROCEDURE

- CAROTID SUBCLAVIAN BYPASS
- --OPEN, BUT NOT TERRIBLY MORBID
- ENDOVASCULAR REPAIR OF THE ANOMALOUS ARTERY
- WHEN NECESSARY, ENDOVASCULAR REPAIR OF THE DUCT OF KUMERALL

BH

- -- 88yo former fighter pilot
- -- Lives at home, cares for wife with dementia
- -- Active, vigorous, drives well
- -- Key concern: "Can't do anything that will keep me from caring for my wife of 60 years"

BH

- --Hypertension (single agent)
- -- Mild COPD
- -- Aortic endograft, 2000
- -- Prostate CA, s/p brachytherapy
- -- Lumbar spine instrumentation, 2003

"BH"

- --Presented with cough to urgent care
- --CXR obtained
- --CT performed
- --Urgent consultation obtained

CXR

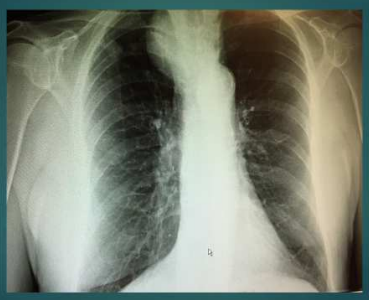

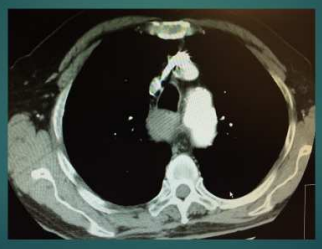

How to Treat?!?

- -- Right carotid – subclavian artery bypass
- -- Exclude aneurysm from flow
- -- Exclude aneurysm from back flow
- --Avoid thoracotomy

Amplatzer Plug

CTA

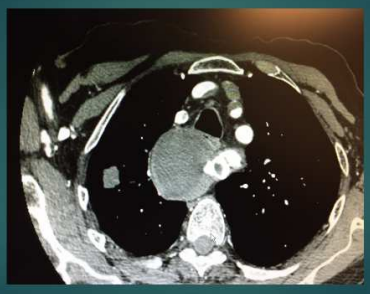


REMEMBER
Follow Up


thank you!